

## Clinical Outcome After Using Small External Fixator in Management Of Distal Radius Fractures : A Prospective Study

Satish Kumar<sup>1</sup> ,Raj Kumar Meena<sup>2</sup> ,P V Siddhartha<sup>2</sup> , Haaris Rasheed<sup>3</sup> ,Vikash Chandra Kesharwani<sup>3</sup> ,Jayeshkumar Kalubhai Kakadiya<sup>3</sup> , Krithika T T<sup>4</sup>

<sup>1</sup>(Consultant ,Orthopaedics And Associate Professor PGIMER , Dr Ram Manohar Lohia Hospital , New Delhi)

<sup>2</sup>(Senior Resident Orthopaedics , PGIMER , Dr Ram Manohar Lohia Hospital , New Delhi)

<sup>3</sup>(Post Graduate Trainee, Orthopaedics , PGIMER , Dr Ram Manohar Lohia Hospital , New Delhi)

<sup>4</sup>( Junior Resident(Non Academic) Orthopaedics PGIMER , Dr Ram Manohar Lohia Hospital , New Delhi)

### Abstract

**Background:** A prospective study was done to evaluate the effect of the small external fixator in the management of acute intra-articular fractures of the distal radius.

**Methods:** Between July 2013 and June 2015, 30 consecutive patients with articular fractures of the distal radius were treated by closed reduction under image intensifier and external fixation with small external fixators. The mean age at the time of surgery was 46.6 years . The follow-up period was 12 months .

**Results:** All fractures united in a mean of 5.6 weeks . At the final follow-up, the mean range of motion was 55.3<sup>0</sup> in flexion, 56.6<sup>0</sup> in extension, 21.0 in ulnar deviation, 9.0<sup>0</sup> in radial deviation, 70.3<sup>0</sup> in pronation, and 67.1<sup>0</sup> in supination. The overall clinical and functional outcomes, according to the scoring system of Gartland and Werley, showed that 13 patients (43.3%) had excellent results, 12 (40.0%) had good results, 3 (10.0%) had fair results, and 2 (6%) had poor results.

**Conclusion:** Closed reduction under image intensifier and external fixation with the small external fixator is useful and effective in the management of intra articular fractures of the distal radius.

**Keywords:** external fixator, articular fracture, distal radius, K Wire

### I. Introduction

Fracture of the distal radius are very common injuries estimated to account for up to one sixth of all fractures .<sup>(1)</sup> The injuries to the lower end of radius are not only encountered in the emergency department but also the mobility and delicate functional requirements of the hand make accurate diagnosis and treatment crucial to the avoiding long term loss of function and disability.<sup>(2)</sup> 75% of the forearm fractures involve the distal radius as noted by WP Cooney et al<sup>(3)</sup> in their study .Treatment of such injuries can be problematic and demanding particularly when the fracture is severely comminuted or has intra articular involvement. The incidence of complications including stiffness and loss of reduction has been reported to be as high as 31%.<sup>(4)</sup> There are diverse options for the management of the fractures including closed reduction with plaster cast immobilization<sup>(5)</sup> , open reduction and internal fixation<sup>(6)</sup> and more recently application of augmented external fixation<sup>(7-9)</sup> . However the reports of treatment methods and results are still conflicting . If the distal radius fracture is severely comminuted intra articularly , the treatment will be challenging . Restoration of articular congruity is the most critical factor for good functional results. Penning et al<sup>(10)</sup> have recommended that external fixator to be used to restore the radial anatomy if 3 or more cortices shows comminution on the antero-posterior and lateral films in conjugation with radial shortening of more than 5 mm and /or intra articular involvement in the radio carpal or radioulnar joint .The aim and objective of this prospective study was to study the clinico-functional and radiological outcomes after application of small external fixator in the management of intra articular fracture of the distal radius .

### II. Material And Methods

This study was conducted at department of orthopaedics at trauma centre of our institute between July 2013 to June 2015.All patients above the age of 18 years and who were medically fit were included in this study. It was prospective study without control and consisted of 30 patients who attended emergency department of our hospital with intra articular fracture of distal end of radius. Initially closed reduction was done for all patients and radiographic confirmation was done after applying plaster of paris slab. Patients were discharged if fracture was stabilized. If fracture could not be stabilized , then patients were admitted for surgery after their consent were taken. Surgery was performed on the same day and consisted of closed reduction under image intensifier and application of mini external fixator using 2 threaded pins in the 2<sup>nd</sup> metacarpal and 2 pins in radius. After reduction under image intensifier and restoration of radial length and wrist congruity , fractures

were fixed and stabilized with the aid of small external fixator. This is a rigid device consisting of 4 threaded pins, clamps and connecting bars. After small skin incisions were made and radius were drilled with a 2mm drill bit, the pins were inserted manually with a universal chuck , 2 proximally to the fracture in the distal radius and 2 in the shaft of the 2<sup>nd</sup> metacarpal bone. After manipulating and distraction , the fracture was reduced and the connecting bars were applied and secured firmly to the threaded pins with clamps The small external fixator was removed after 6 weeks . K wire was used depending on the severity of intra articular comminution . Patients were started on physiotherapy soon after the surgery.

Patients were followed up 2 weeks after surgery and thereafter every month. Functional outcome was evaluated using a modification of scoring system used by Gartland and Werley<sup>(11)</sup> . Range of motion was evaluated using a goniometer measuring dorsal and volar flexion , radial and ulnar deviation , pronation and supination and the sum was calculated as a percentage of the unaffected wrist.

### III. Results And Observations

There were 30 patients in the study group consisting of 18 females and 12 males patient and male to female ratio was 0.66. The mean age of patients at the surgery was 46.6 years. Right extremity was involved in 20 cases while left extremity was involved in 10 cases . In age wise distribution of cases , majority of fracture of distal end of radius occurred in 51- 60 years group followed by 41-50, then 31 -40 and least were in 18-30 years group. All the fractures were united in a mean 5.6 weeks . At the final follow up, the mean range of motion was 55.3<sup>0</sup> in flexion , 56.6<sup>0</sup> in extention , 21.0<sup>0</sup> in ulnar deviation , 9.0<sup>0</sup> in radial deviation , 70.3<sup>0</sup> in pronation and 67.1<sup>0</sup> in supination. Using the scoring system of Gartland and Werley<sup>(11)</sup> , the overall clinical and functional result was excellent in 13 patients(43.3%) , good in 12 patients (40.0%) , fair in 3 patients(10.0%) and poor in 2 patients (6.0%) ( fig 1,2,and 3,4,5) . Three patients had superficial pin tract infection which were treated by oral antibiotics. One patient had wrist pain persisting even after last follow up which was later treated for chronic regional pain syndrome.

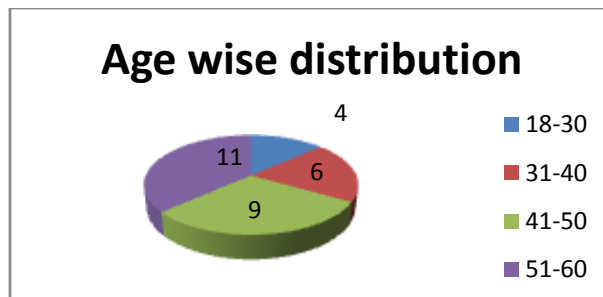


Figure 1: showing age wise distribution of cases

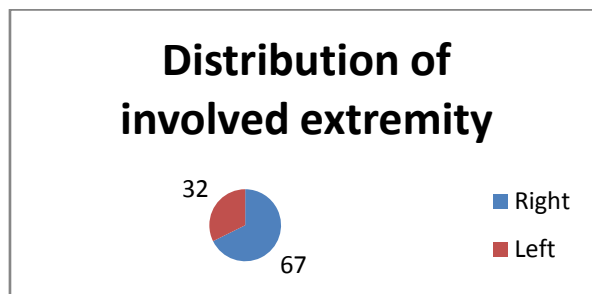


Figure 2: Showing distribution of involved cases in Percentage(%)

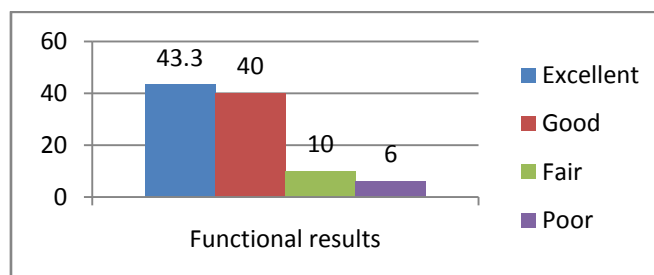


Figure 3: Showing Functional Results based on Gartland and Werley criterion<sup>11</sup>

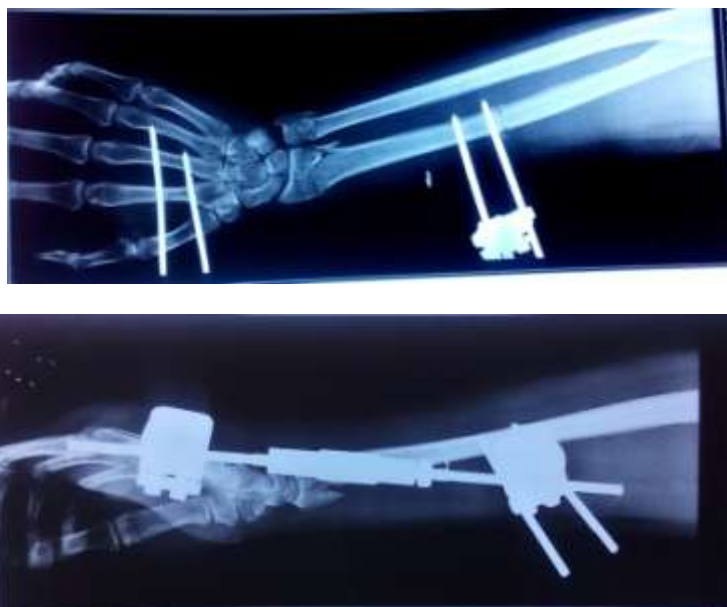


Figure 4 : Radiograph ( AP and Lateral view) showing fracture distal radius fracture external fixator in situ

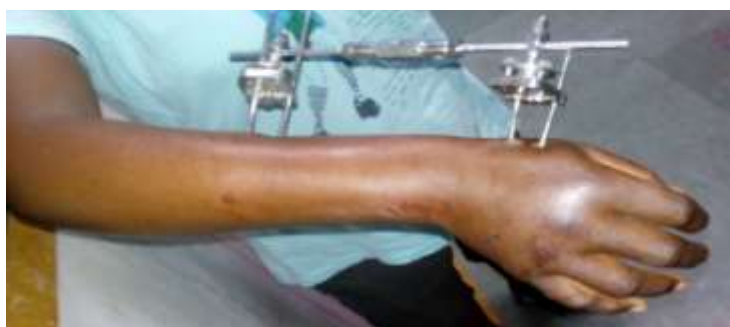

Figure 5 : Clinical photograph showing small external fixator in situ

#### **IV. Discussion**

We used small external fixator to immobilize the intra articular fracture of the distal radius and overall functional result based scoring system of Gartland and Werley<sup>(11)</sup> were excellent or good in 25 patients(83.3%) , fair in 3 Patients (10.0%) and Poor in 2 Patients(6%) . Our findings were comparable to a study done by Cooney et al<sup>(12)</sup> using transarticular external fixator without systemic use of bone graft in 60 patients with an average age of 63 years. 88 % of these fractures were intraarticular . The average follow up was 2.4 years. There was a 2% incidence of arthritis. There was no residual finger stiffness. The Final outcome was rated excellent or good in 87% and fair in 13%. Leung et al<sup>(13)</sup> studied younger patients with average age 40.9 years with intra articular fractures in 96.4% . All Patients were bone grafted and the trans articular fixator was only left in place for 3 weeks. A brace was used for a further 3 weeks . 2 % showed post traumatic arthritic changes. Excellent or good result were seen in 90.4% of the cases and fair in 9.6% . In their series , bone grafting from iliac crest did not lead to significant complications.

Jenkins et al<sup>(14)</sup> performed a prospectively controlled study in which patients with a distal radius fracture were treated either by plaster or by external fixation . 94% of the external fixator group had a periarticular fixation. The external fixator proved more effective in holding the manipulated position and the radiological loss of union was minimal when compared with plaster group.

The result of this study showed that the intra articular fracture of distal radius is a complex injury which needs careful management. It is one of the common injuries in orthopaedic trauma. In cases of displaced intra articular fracture, repair focuses on precise anatomic reduction and articular alignment.<sup>(15)</sup> Restoration of the anatomy and articular surface may prevent the onset of arthritis and improve function.<sup>(16)</sup> The union time in our study was 5.6 weeks which was comparable to other studies.<sup>(17,18)</sup>

In our study, incidence of post traumatic arthritis was 2.2% which was comparable to other studies.<sup>(12,13)</sup> With better understanding of the disrupted anatomy , biomechanics of the injury pattern and improved imaging techniques , surgeons today have the opportunity to improve maximum functional outcome and reduce the possibility of post traumatic arthritis.<sup>(16)</sup> Complications reported with external fixation include

pin site infection, superficial branch of radial nerve irritation, reflex sympathetic dystrophy, carpal tunnel syndrome, stiffness, shaft fractures and post-traumatic arthritis.<sup>(19,13)</sup> The use of external fixation requires strict adherence to a post-operative protocol which involves pin care to avoid septic complications around pin sites. Unless this is achieved, external fixation cannot be expected to provide reproducible results.<sup>(20)</sup>

## V. Conclusion

Closed reduction under image intensifier and external fixation is useful and effective in the management of intra-articular fracture of the distal radius. Meticulous reduction and rigid fixation with small external fixation device is the key factor in achieving good final clinical results. Our study had limitations of small sample size and absence of long-term follow-up.

## References

- [1]. Hollingsworth R, Morris J. The importance of the ulnar side of the wrist in fractures of the distal end of the radius. *Injury* 1976;7:263-6.
- [2]. Older TM, Stabler EV, Cassebaum WH. Colles' fractures: evaluation and selection of therapy. *J Trauma*. 1965;5:469-76.
- [3]. Alffram PA, Bauer GC. Epidemiology of fractures of the forearm. A biomechanical investigation of bone strength. *J Bone Joint Surg Am*, 44, 1962, 105-114.
- [4]. Cooney WP III, Dobyns JH, Linscheid RL. Complications of Colles' fracture. *J Bone Joint Surg Am* 1980;62:613-9.
- [5]. Robertsson GO, Jonsson GT, Sigursjonsson K. Epidemiology of distal radius fractures in Iceland in 1985. *Acta Orthop Scand* 1990;61:457-9.
- [6]. McBirmie J, Court-Brown CM, McQueen MM. Early open reduction and bone grafting for unstable fractures of the distal radius. *J Bone Joint Surg Br* 1995;77:571-5.
- [7]. Pennig D. Dynamic external fixation of distal radius fractures. *Hand Clin* 1993;9:587-602.
- [8]. Pennig D, Gausepohl T. Extraarticular and transarticular external fixation with early motion in distal radius fractures and malunions. *Orthop Surg Tech* 1995;9:51-65.
- [9]. Seitz WH, Putman MD, Dick HM. Limited open surgical approach for external fixation of distal radius fractures. *J Hand Surg Am* 1990;15:288-93.
- [10]. Pennig D, Gausepohl T. External fixation of the wrist. *Injury* 1996;27:1-15.
- [11]. Gartland JJ, Werley CW. Evaluation of healed Colles' fractures. *J Bone Joint Surg Am* 1951;33:895-907.
- [12]. Cooney WP. External fixation of distal radius fractures. *Clinical Orthopedics* 1983;180:44.
- [13]. Leung KS, Shen WY, Leung PC, et al. Ligamentotaxis and bone grafting for comminuted fractures of the distal radius. *Journal of Bone and Joint Surgery* 1989;71:838.
- [14]. Jenkins NH, Jones DG, Johnson SR, et al. External fixation of Colles' fracture: An anatomical study. *JBJS* 69-B;1987:207
- [15]. Zanolini RM, Louis DS. Intra-articular fractures of the distal end of the radius treated with an adjustable fixator system. *J Hand Surg Am* 22(3) 428-440, 1997.
- [16]. Knirk JL, Jupiter JB: Intra-articular fractures of the distal end of the radius in young adults. *J Bone Joint Surg Am* 68(5):647- 659, 1986.
- [17]. Werber KD, Raeder F, Brauer RB, Weiss S. External fixation of distal radial fractures: four compared with five pins. *J Bone Joint Surg Am* 2003;85:660-6.
- [18]. Nakata RY, Chand Y, Matiko JD, Frykman GK, Wood VE. External fixators for wrist fractures: a biomechanical and clinical study. *J Hand Surg Am* 1985;10:845-51.
- [19]. Paksima N, Panchal A, Martin A, Steven M, Mehlman CT, Hiebert R. A meta-analysis of the literature on distal radius. Review of 615 articles. *Hospital for Joint Diseases* 2004;vol 62:1& 2
- [20]. Gausepohl T, Pennig D, Mader K. Principles of external fixation and supplementary techniques in distal radius fractures. *Injury Int J Care Injured* 2010 ;31:56-70